



**PATIENT**

Ellie Dupuy

**SPECIES**

Canine

**BREED**

Shepherd Mix

**SEX**

FS

**AGE**

12 years

**WEIGHT**

58 lbs

**INTERPRETED BY**

Maggie Machen  
 Lamy, DVM, DACVIM  
 (Cardiology)

**IMAGING PERFORMED BY**

Sara Hansen, SDEP  
 Clinical Sonographer

**HOSPITAL NAME**

Alpine Animal  
 Hospital

**REFERRING VET**

Dr. Vasquez-Perez

**INVOICE**

32131

**DATE**

8/3/23

**PRESENTING CLINICAL SIGNS**

History: Grade 5/6 heart murmur weak femoral pulses distended abdomen positive fluid wave upon abdominal palpation suspected ascites.  
 Current Medications Furosemide 50mg - 1T BID; Enalapril 10mg - 1T BID  
 No sedation. ECG and CXR declined.

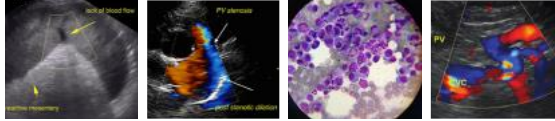
**ECHOCARDIOGRAM FINDINGS**

2D, m-mode, color flow and doppler imaging is available. Severe left ventricular dilation with diminished systolic function. Increased EPSS and increased sphericity. Decreased LV wall thickness. Severe left atrial enlargement. The mitral valve appears mildly thickened, with no obvious prolapse into the left atrial lumen. Moderate central mitral regurgitation; decreased velocity. The tricuspid valve appears mildly thickened. Moderate right atrial and ventricular dilation. Mild to moderate tricuspid regurgitation. Normal velocity. The aortic valve is normal with a normal outflow velocity. No AI. Normal pulmonic valve with decreased outflow velocity. No PI. Scant pericardial effusion seen. No pleural effusion noted. Ascites confirmed. No obvious cardiac tumors. Tachycardia throughout with irregular rhythm.

**CARDIAC CHART**

CANINE CARDIAC PARAMETERS	MR VMAX (m/s)	TR VMAX (m/s)	LA/AO (Boon method)	LA/AO (Heart Base; Swe)	FS (%)	EF (%)	EPSS (cm)	
NORMAL PARAMETER	4.5-5.5	<2.7	1.3	<1.6	28-40	40-100	<0.6	
PATIENT	4.2	2.2	2.2	2.2	14	26	0.9	
CANINE CARDIAC PARAMETERS	HR (BPM)	AV VMAX (m/s)	PV MAX (m/s)	BODY WEIGHT (kg)	LA 2D short axis Base view (cm)	LVIDd Avg; 2D and m-mode short axis (cm)	LVIDs Avg; 2D and m-mode short axis (cm)	
NORMAL PARAMETER	50-100	0.7-1.7	0.7-1.6	BELOW	BELOW	BELOW	BELOW	
PATIENT	NM	1.5	0.8	26.4	4.5	5.5	4.7	
*Normal chamber parameters expressed as a mean value (SD)					3	1.27 (5.3)	2.46 (2.46)	1.36 (5.5)
<b>BODY WEIGHT DEPENDENT PARAMETERS</b>					5	1.40 (4.5)	2.74 (5.2)	1.60 (4.7)
					10	1.50 (3.8)	3.27 (3.5)	2.06 (3.1)
					15	1.83 (2.0)	3.71 (2.4)	2.43 (2.1)
					20	2.02 (1.9)	4.14 (2.2)	2.80 (2.0)
					25	2.18 (2.4)	4.48 (2.9)	3.10 (2.5)
					30	2.33 (3.3)	4.83 (3.9)	3.39 (3.4)
					35	2.48 (4.3)	5.17 (5.0)	3.69 (4.5)
					40	2.62 (5.2)	5.48 (6.1)	3.96 (5.4)
					50	2.88 (7.1)	6.07 (8.3)	4.46 (7.4)

Adapted from June Boon, Veterinary Echocardiography, 1998  
 Rishniw M and Hollis NE, J Vet Intern Med 2000; 14:429-435  
 Hansson et al, Vet Rad and Ultrasound 2002  
 Bonagura et al. Echocardiography: principles of interpretation, Vet Clin North Am 15:1177, 1995



**PATIENT**

Ellie Dupuy

**SPECIES**

Canine

**BREED**

Shepherd Mix

**SEX**

FS

**AGE**

12 years

**WEIGHT**

58 lbs

**INTERPRETED BY**

Maggie Machen  
Lamy, DVM, DACVIM  
(Cardiology)

**IMAGING  
PERFORMED BY**

Sara Hansen, SDEP  
Clinical Sonographer

**HOSPITAL NAME**

Alpine Animal  
Hospital

**REFERRING VET**

Dr. Vasquez-Perez

**INVOICE**

32131

**DATE**

8/3/23

**INTERPRETATION OF THE FINDINGS & FURTHER RECOMMENDATIONS**

Unfortunately, this patient has end-stage cardiomyopathy and systolic dysfunction. This is causing dilation and volume overload of both the left and right heart and severe biatrial dilation. Moderate MR and mild to moderate TR are identified with mild pulmonary hypertension. No additional issues are seen. **A baseline ECG is strongly recommended as the patient has an irregular tachycardia throughout the study. Atrial fibrillation is a consideration, which would warrant further therapy.**

Systolic failure can be primary in nature (DCM) or secondary to taurine deficiency, hypothyroidism, myocarditis, tachycardia-induced cardiomyopathy, or infiltrative disease such as lymphoma. In a senior large breed, DCM is suspected; however, a diet history should be obtained due to the recent correlation between grain free/boutique/exotic diets and cardiomyopathy (with a diet change and/or supplementation if indicated). Thyroid status can be assessed, a cTnI submitted, etc., however prognosis at this stage is unchanged.

Given the severity of disease seen here in addition to reported ascites, biventricular CHF is suspected, and treatment is recommended as below. No dyspnea is reported; however, should the patient become unstable, highly recommend hospitalization for oxygen support and IV therapy. **The importance of further arrhythmia evaluation cannot be stressed enough, as treating CHF without addressing the heart rate is unlikely to improve clinical signs.** Even if able to be stabilized and the response to medications is good, this patient will always be at high risk for recurrent CHF, development of syncope, malignant arrhythmias and/or sudden death going forward. The prognosis is poor at this stage in the disease process, with an average survival time of <6 months.

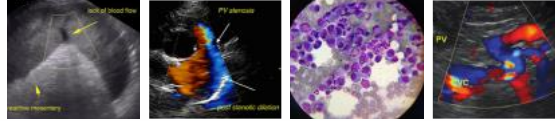
Omega fatty acid supplementation and mild salt restriction may be of some long-term benefit. Moderate activity restriction is advised. Monitor for development of a cough, worsening labored breathing, abdominal distention, exercise intolerance or collapse episodes in the future. Monitoring of sleeping breathing rates at home is recommended to assess response to medications and recurrence of CHF in the future.

**PLAN:**

If patient appears unstable or tachypneic, consider referral for 24-hour supportive care. An ECG should be performed ASAP. Baseline BP are recommended. Recommend the following oral medications: Institute aldosterone antagonist Spironolactone 1-2mg/kg PO q12h. Institute diuretic furosemide 1-2mg/kg PO q12h. Institute Pimobendan 0.3mg/kg PO q12h. Institute taurine supplement 1000mg PO q12h. Consider diet history, thyroid status, etc.

Recommend recheck renal panel and blood pressure in 1-2 weeks to ensure tolerance to medications. If BP >130mmHg and doing well at home, institute ACEI 0.5mg/kg PO q12h at that time.

Recheck echocardiogram in 6 months, sooner if problems arise in the interim.



**PATIENT**

Ellie Dupuy

**SPECIES**

Canine

**BREED**

Shepherd Mix

**SEX**

FS

**AGE**

12 years

**WEIGHT**

58 lbs

**INTERPRETED BY**

Maggie Machen Lamy, DVM, DACVIM  
(Cardiology)

**IMAGING PERFORMED BY**

Sara Hansen, SDEP  
Clinical Sonographer

**HOSPITAL NAME**

Alpine Animal Hospital

**REFERRING VET**

Dr. Vasquez-Perez

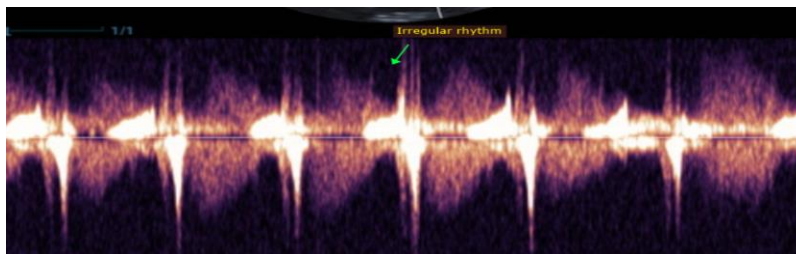
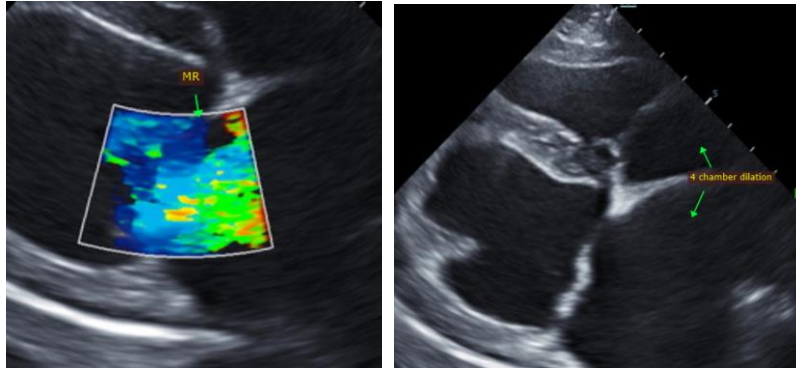
**INVOICE**

32131

**DATE**

8/3/23

**IMAGES**



The information and recommendations provided are based on the images presented by the referring veterinarian. No evaluation can be communicated regarding pathology that was not visible in the image/video clips provided.

Thank you for this referral. If the clinical or image interpretation does not parallel your findings or if I can be of any further assistance, please contact me.

Maggie Machen Lamy, DVM  
Diplomate of the American College of Veterinary Internal Medicine (Cardiology)  
info@sonopath.com